

CASE STUDY

- 95% WOUND REDUCTION IN 7 WEEKS
- 7 ACTIGRAFT APPLICATIONS

PATIENT:

58 Year Old, Female

PAST MEDICAL HISTORY:

Peripheral neuropathy, Diabetes Melitus Type 2

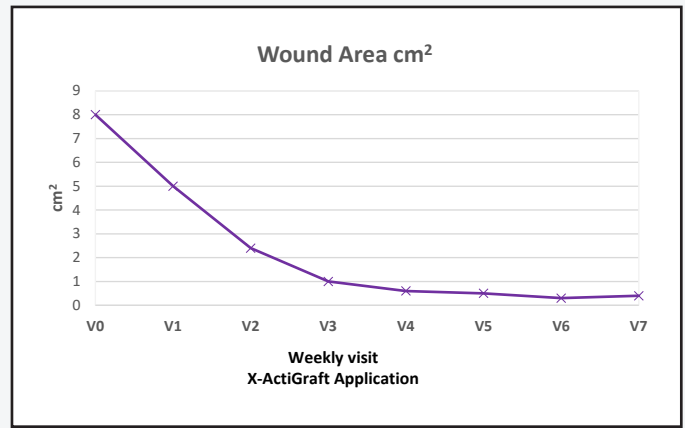
WOUND HISTORY:

- 72-month-old right plantar foot wound

PAST TREATMENTS:

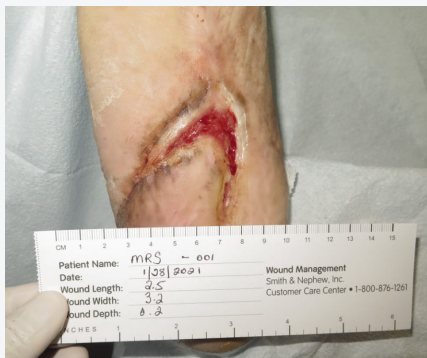Saline, Honey, Iodoflex, Alginate, OTC Topical Antibiotic, Surgical Debridement, Xeroform

ACTIGRAFT TREATMENT PROGRESSION:



V=Weekly Application

Week 1



Week 7

